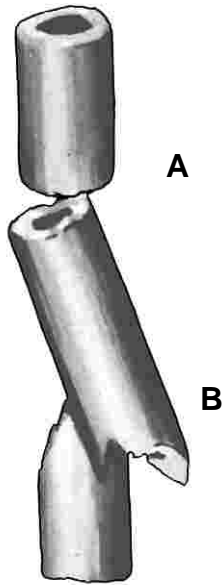



9 MULTIPLE FRAGMENTS



Double Fractures

These are dealt with just as single simple fractures, each fracture being transfixed in turn. Security of fixation becomes a little more complex because "a chain is no stronger than its weakest link". Each fracture influences the overall stability of fixation of the bone.

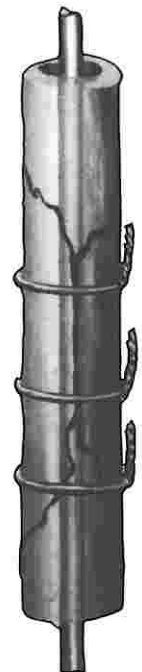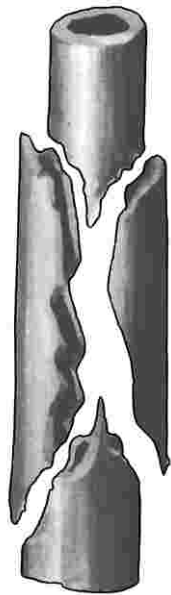
Fracture (a) being smooth might have a tendency to twist; fracture (b) is not likely to rotate because the fracture surfaces are irregular and can be locked in position.

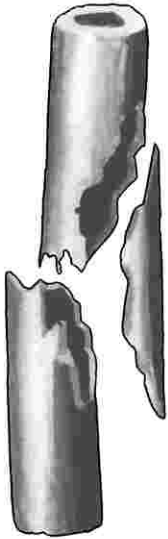


Double Butterfly Fragments

It is obvious that such a fracture cannot be stably transfixed by a pin or a nail alone. The longitudinal muscle pull will cause the butterfly fragments to separate. The main fragments will telescope to produce marked shortening.

Supplemental circular wires provide stability and in this type fracture will prevent twisting of the bone.

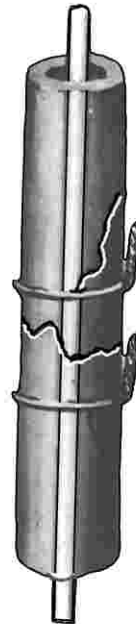




Single Butterfly Fragments

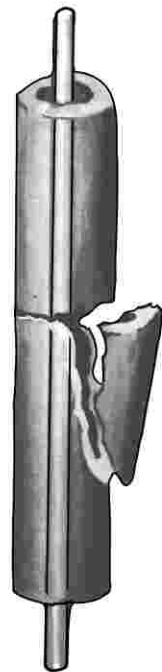
A fracture of this type may or may not require supplemental wiring. If reduction provides firm contact between the ends of the proximal and distal fragments, telescoping and shortening cannot occur. If this fracture line is notched or irregular, this alone might insure against twist. Longitudinal muscle pull might hold the butterfly fragment in position.

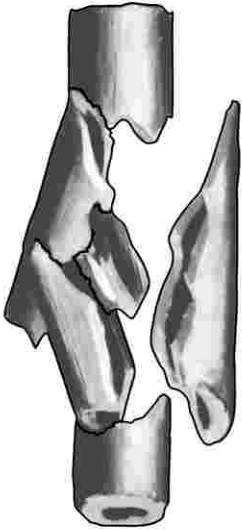
Added circular wires will provide better fixation, better bone contact, and prevent twist.



Half Butterfly Fragments

The factors involved here are similar to those mentioned above. In the fracture shown, not a great deal can be accomplished by circumferential wiring. Wiring will not increase the stability of fixation and will not influence twist because the main fracture is smooth and transverse. Wiring will hold the detached fragment in snugger contact with the distal fragment.

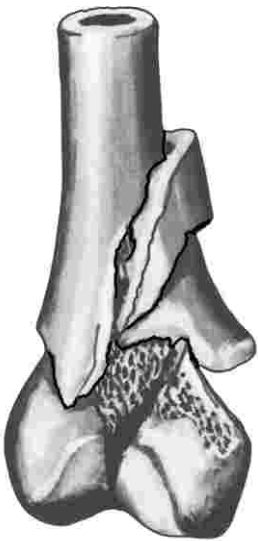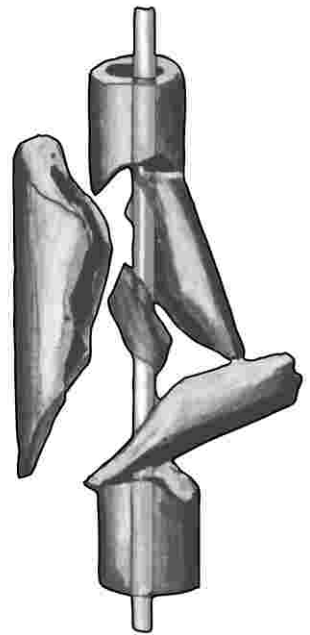




Bag of Bones Fracture

This fracture can tax the surgeon's ingenuity to the utmost. The proximal and distal fragments can be satisfactorily realigned on the pin. Circular wires may prove a marvelous adjunct or prove ineffective.

The tendency toward telescoping can cause the wires to slip and loosen, to break or untwist. If stability is doubtful, external splinting or traction should be used.

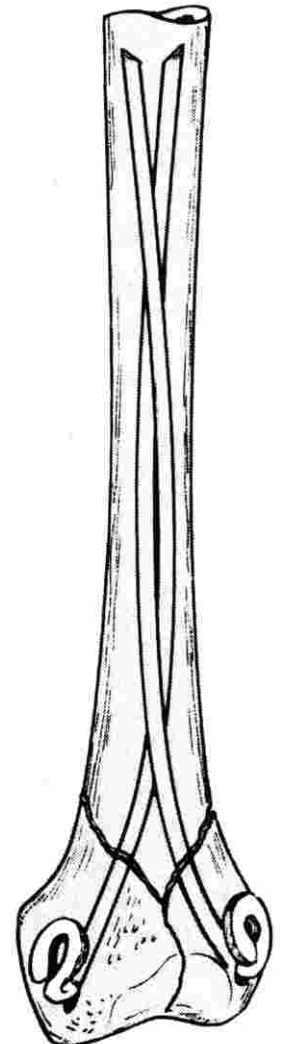
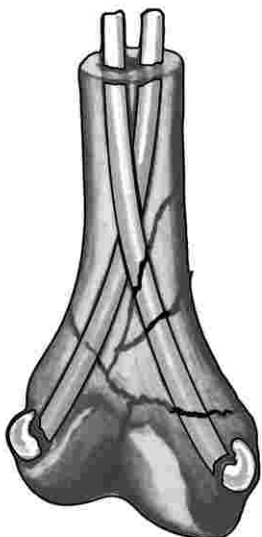


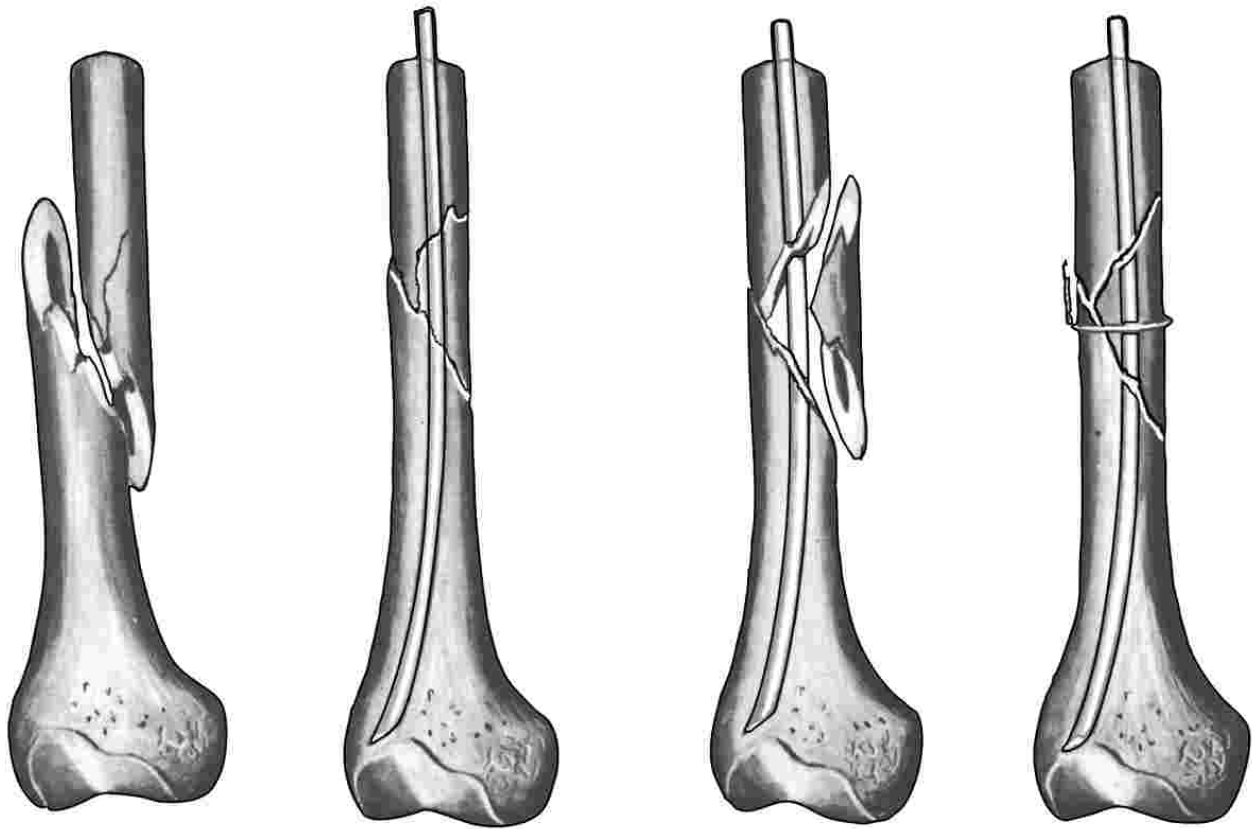
Comminution Near Joints

Pinning of the elbow region requires **open reduction**.

Closed reduction and pinning have often been found more effective in other regions. This is particularly true in comminuted fractures of the neck of the humerus, the distal radius, the distal end of the femur, and both extremities of the tibia.

When traction is instituted in the proper direction, the fascial envelope tends to compress these fragments into a satisfactory relationship. When an incision is made, this helpful factor is lost, and reduction becomes more difficult. And when double pins can be used, as in the supracondylar femur fracture, there is little tendency to telescoping or rotation.





A properly reduced Spiral Fracture should be stably help by pinning alone. Circular wires are occasionally needed, because most spiral fractures are in reality comminuted. The x-ray film can be extremely misleading in this fracture.

About Circumferential Wiring

Comminuted fractures warrant serious consideration because they are becoming more and more to be reckoned with. This is to be expected, now that we are dealing with older age groups and with more violent accidents. In our experience the complemental use of circular wires with medullary pins has on the whole been most satisfactory, both as to stability of fixation and bone healing.

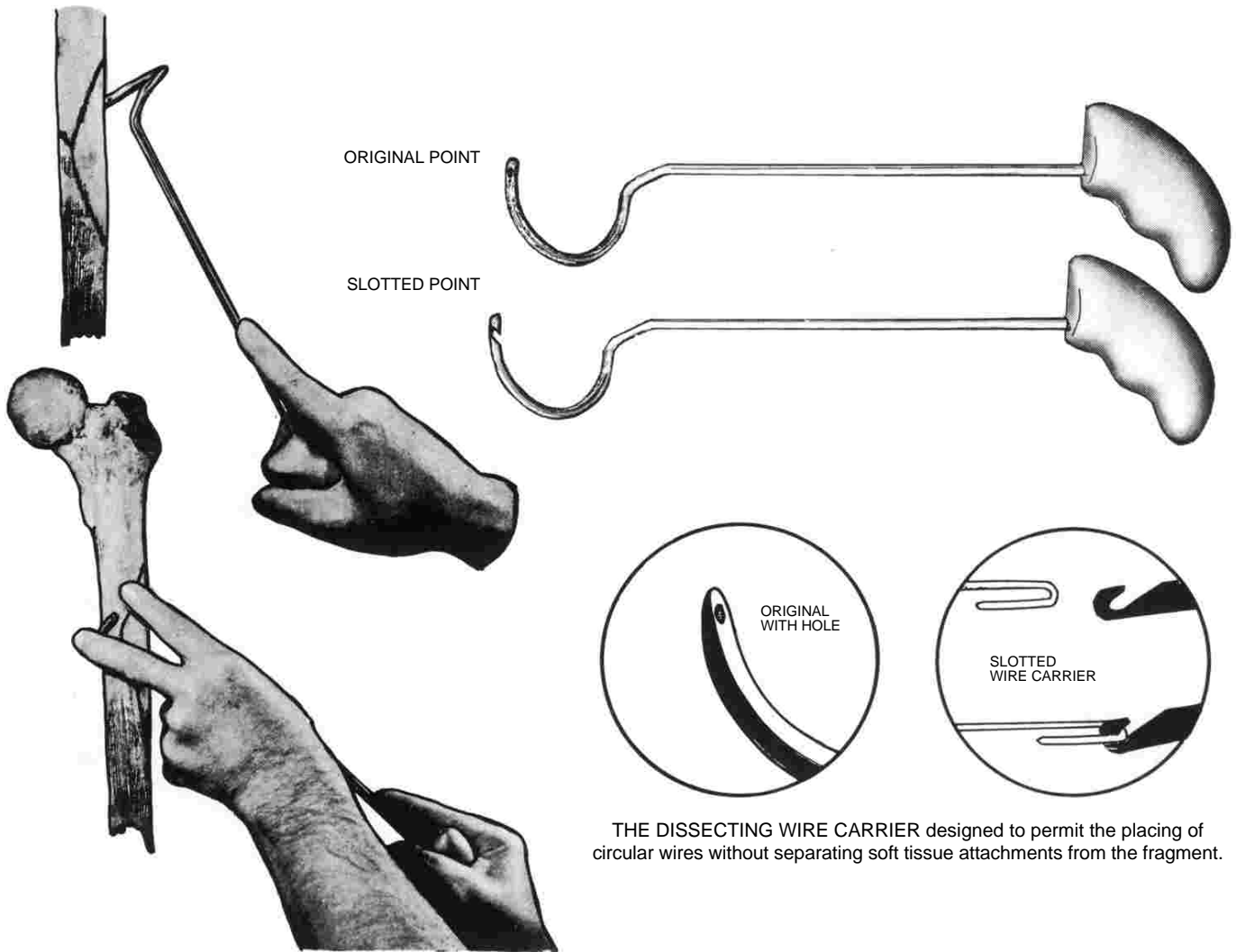
It must be pointed out that circular wires should be meticulously avoided in children. They constrict growing bone.

Circular wires have not always enjoyed a good reputation. Wiring alone cannot be depended

upon for good fixation. They may slip and become loose; they may break or untwist.

To be used effectively they must be applied without cutting the soft tissue attachment from bone fragments. To do so lessens the healing potential. The soft tissue attachments keep the wire from crawling or slipping into the fracture line where it would become loose and ineffective or even interfere with healing.

The wire must be large enough and strong enough to remain snug after twisting. And above all, the fracture must be amenable to wiring. Multiple short fragments cannot be held in this manner.



Applying Circular Wires

Comminuted fractures can present quite a problem at times with any type operation. Yet many times reduction and fixation can be accomplished as a semi-open procedure.

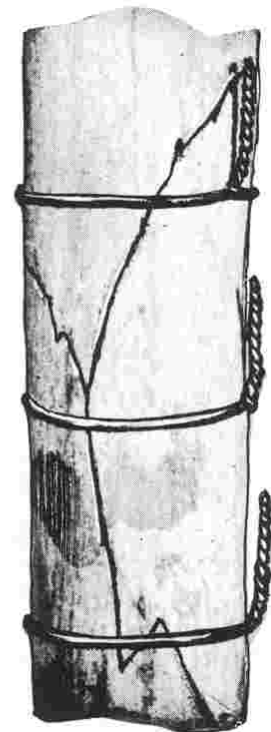
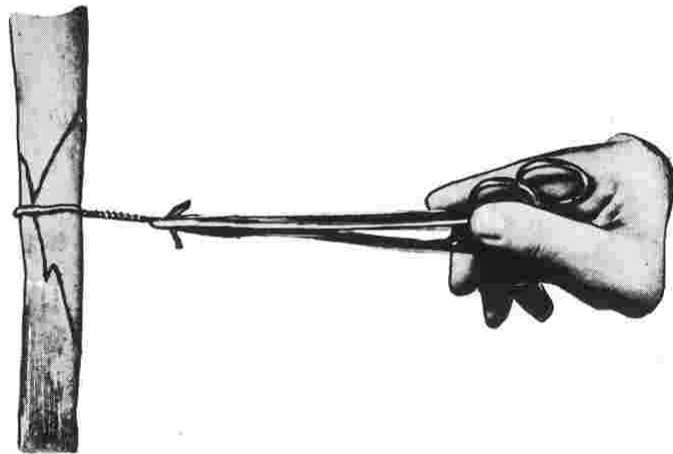
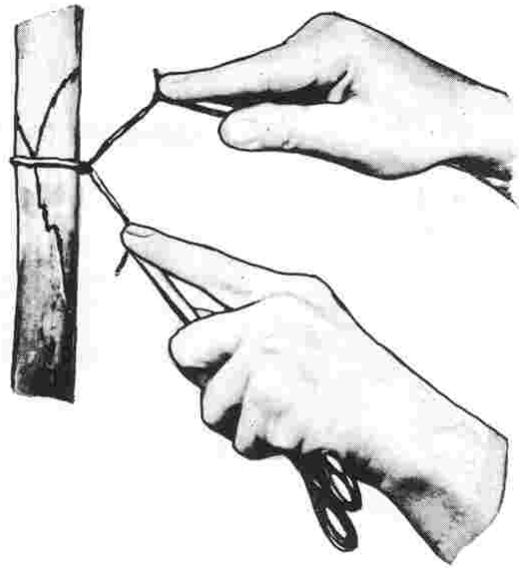
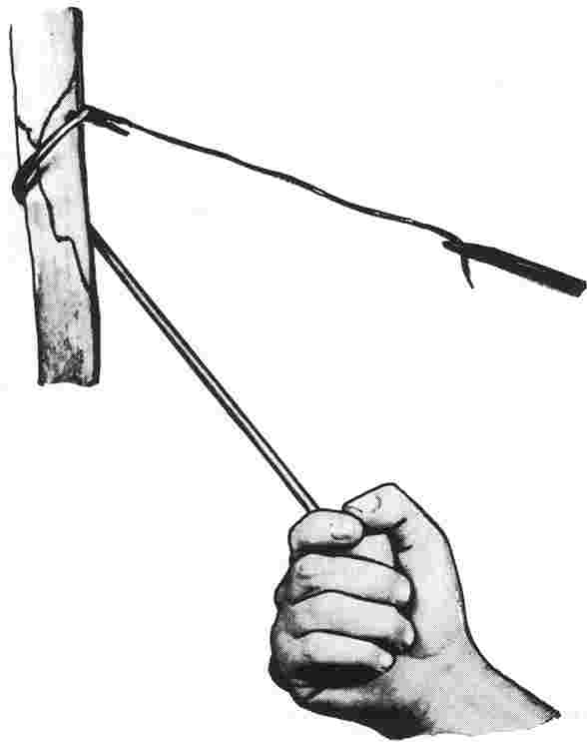
It is desirable to limit dissection and surgical trauma as much as possible. As the surgeon becomes more experienced he develops an acute sense of "feel" in his fingers so that he becomes less and less prone to expose the bone to direct vision.

To facilitate this conservation type operation the wire carrier above was developed after several years' experimentation. The wire carrier has certain unique features.

The original wire carrier has a point with the

traditional eye through which the wire can be threaded. The slotted wire carrier makes grabbing the cerclage wire much easier, greatly reducing operating time and providing less muscle trauma. On both, the point has been shaped as a dissecting tool with a moderately sharp cutting edge. The inside of the tip is flattened, the outside tapered.

This design makes it possible to hug the wall of the bone as it passes peripherally. The point can be pushed through the soft tissue attachments of the bone. Two palpating fingers in the wound allow the experienced surgeon to pass the instrument a visually, and by keeping the point in contact with the bone, important nerves and blood vessels are not endangered.

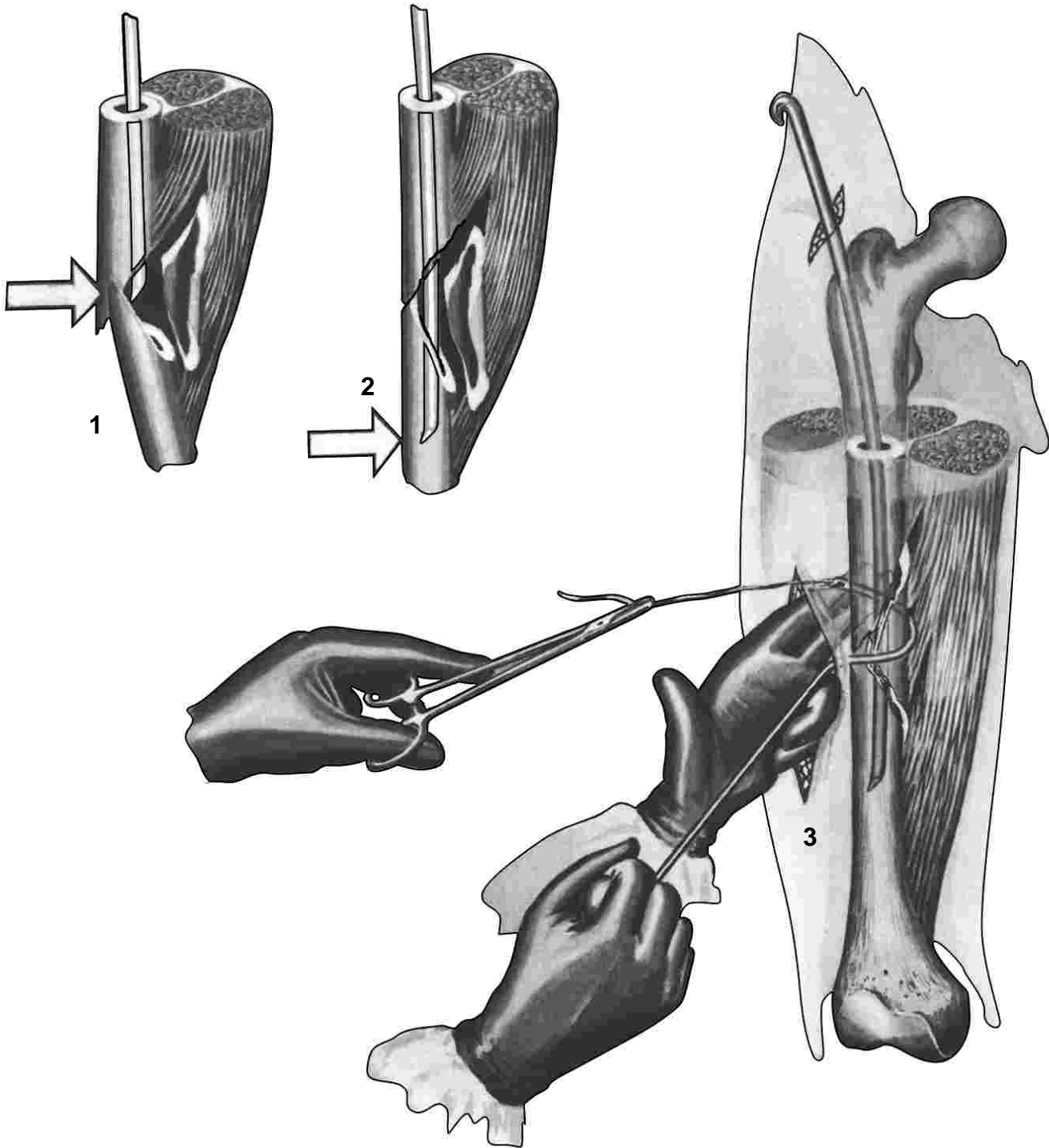


Applying Circular Wires (CONTINUED)

The peculiar curve of the instrument is to permit it to be passed around two-thirds of the circumference of the bone so the eye can visualize for threading. With a true semicircle it is difficult to bring the point into view for threading.

The pistol grip handle permits effective manipulation of the instrument.

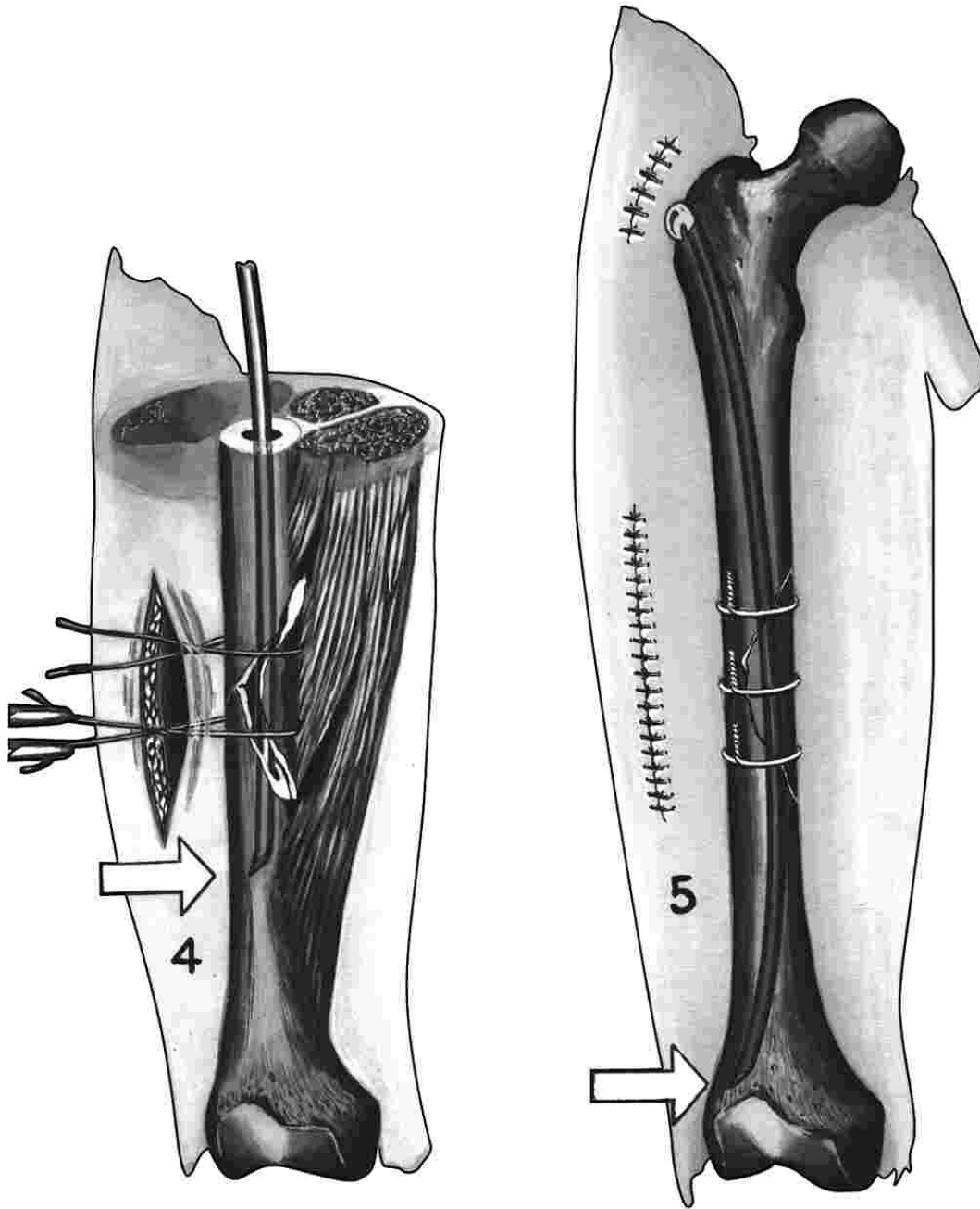
The wire is tightened by twisting, using two needle holders. Do not use artery forceps if it is intended to use them again for soft tissue.



Technic Comminuted Fractures

(1) Drive the pin to fracture site.
(2) Align proximal and distal fragments, engage pin in distal fragment, but do not drive pin home.

(3) Leave soft tissue attached to fragments. Pass wire-carrier close to bone, through the muscle attachment using the guiding fingers. Thread point of wire carrier to place wire loop around the bone.



Technic Comminuted Fractures

(CONTINUED)

(4) Use wire loops instead of bone clamps to maneuver fragment or fragments into position. Twist wire snugly but not tight.

(5) Drive pin home, tighten wires to complete operation.