

8 STABILITY OF FIXATION



A straight rod may be forced into a curve by passing it through three pressure rollers.

The Proximal Fragment

We are dealing with two main fragments which must be held in firm contact with each other. Rocking or twisting of the fragments at the fracture site must be minimal. A medullary rod can accomplish this only if it is given a secure purchase on each individual fragment.

The proximal fragment is the easier to deal with, because of the principle of three-point pressure.

Observe the rollers above. To bend anything one uses three-point pressure. But many factors will influence the behavior of the rod.

(1) The greater the pressure of the rollers, the more the rod will bend.

(2) Bring the rollers close together, and the curve


of the rod increases.

(3) Spread the rollers apart, and the curve of the rod decreases.

(4) If the rod is soft or malleable, it conforms readily to the curvature which it tends to hold permanently.

(5) The more resilient the rod, the less readily it conforms to the curve and the more it tends to return to its original alignment (straight).

The resilience of the pin is such that if it is sprung like a bow, it will tend to return forcefully to its straight axis. On the other hand it can be set into a permanent curve by shaping it with the bending iron.

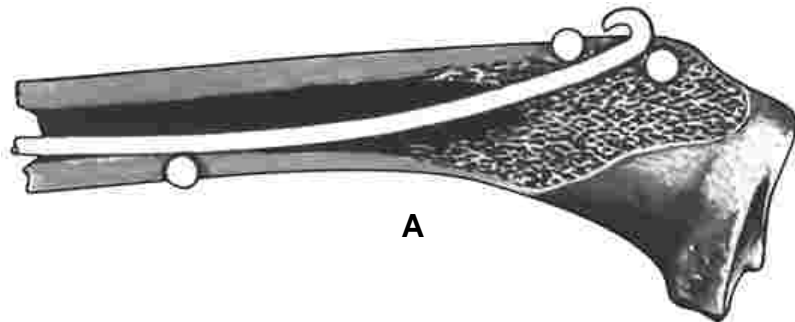


Influence of the Resiliency of the Rod

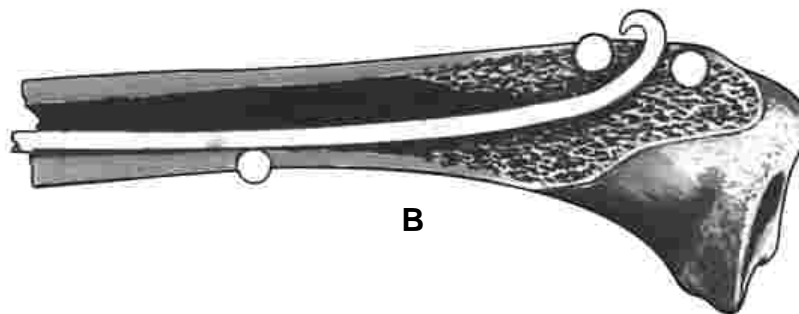
A straight rod or pin which is driven axially into the medullary cavity of a bone, through an opening in the side, is compressed between three pressure points, like the rod passing between the rollers. Thus the rod is forced into a curve of some degree.

(A) A soft or malleable rod assumes a permanent curve and exerts minimum pressure at these three points.

(B) A resilient rod tends to realign itself within the bone, exerting dynamic pressure at these three points.



A

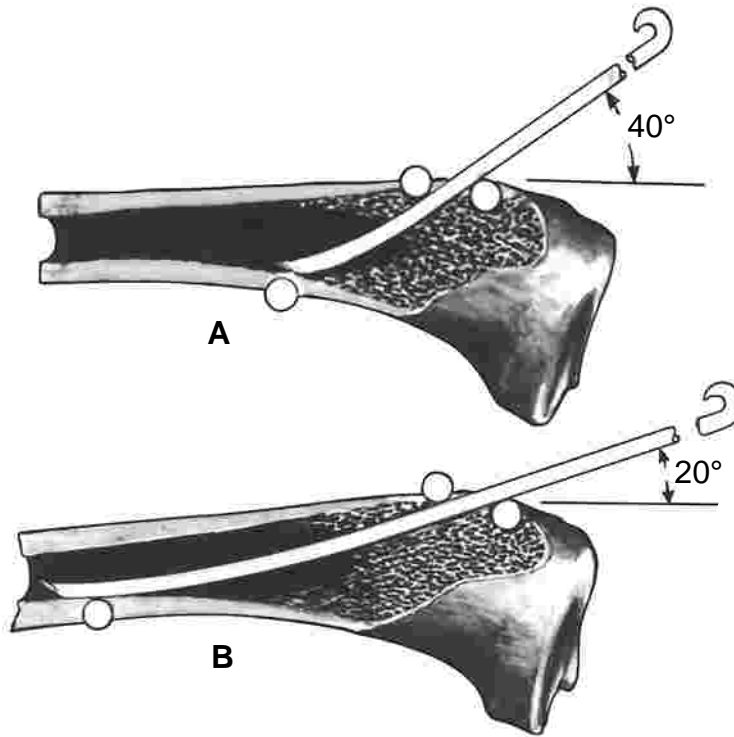


B

Influence of the Precurving Pin

(A) As shown above, a straight resilient rod exerts strong pressure at three points. It has been forced into a curve and is continuously trying to return to its straight axis. It is dynamic.

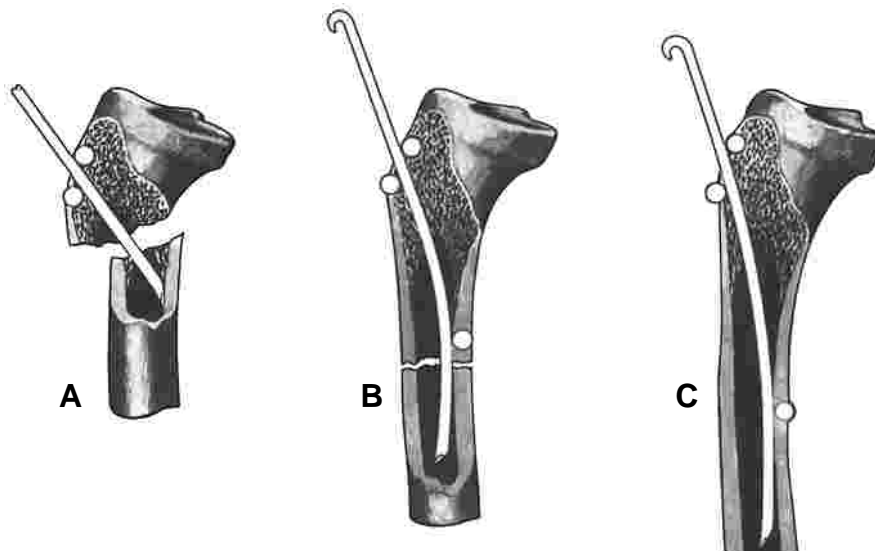
(B) The rod exerts less or no pressure at these three points if it is preshaped into a curve. The curved pin retains its curve. Since it is not trying to return to its straight axis, it becomes static.



Influence of the Angle of Insertion

(A) The greater the angle of insertion, the greater the three-point pressure and the more stable the fixation. Here the “roller” is exerting more pressure, and the rollers are close together.

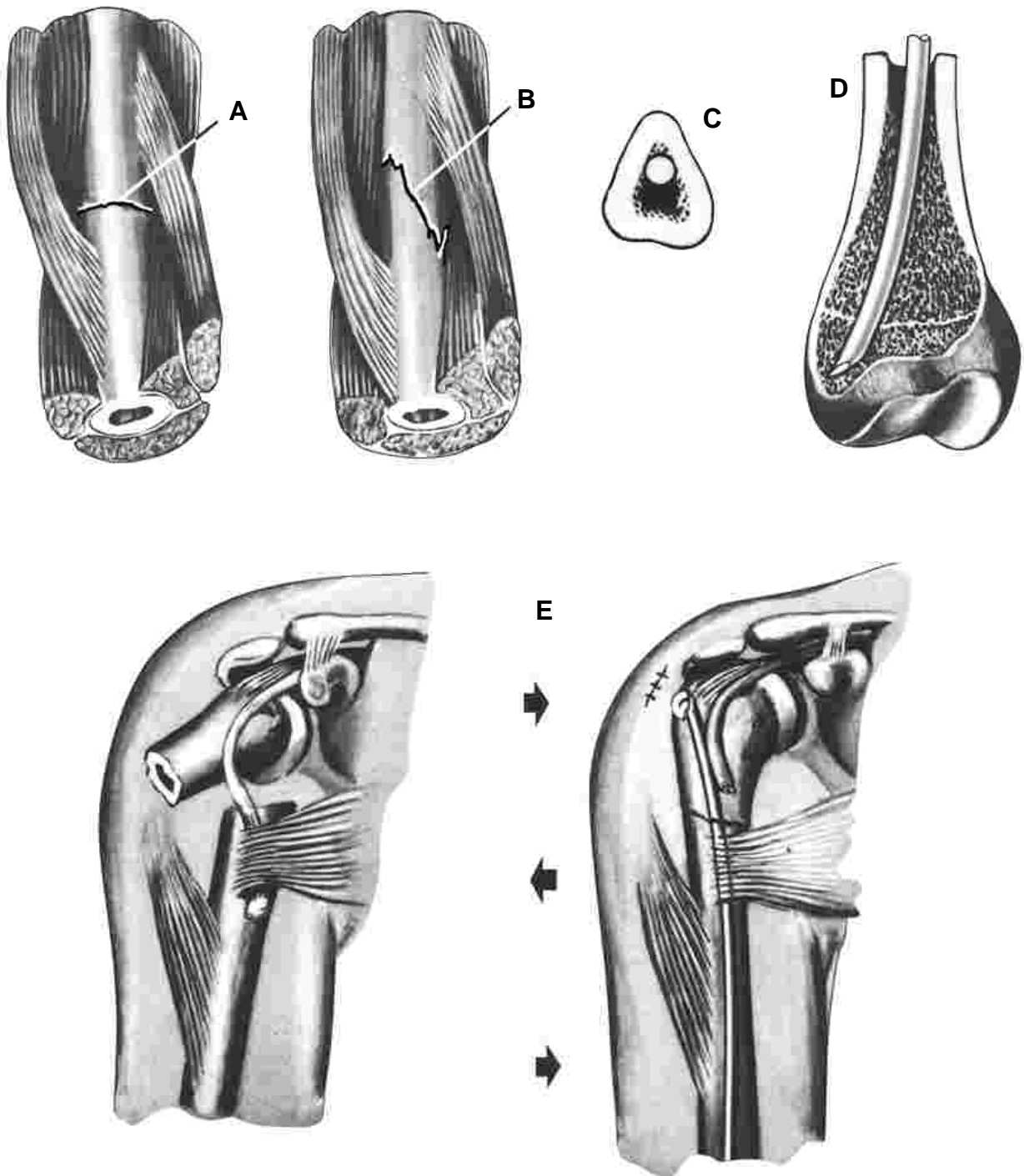
(B) The lesser the angle of insertion, the lesser the three-point pressure and the less stable the fixation. Here the “rollers” are exerting less pressure and have been moved further apart.



Influence of the Length of the Fragment

- (A) Unstable – Three point-pressure absent.
- (B) Stable – Good three-point pressure.
- (C) More stable – Good three-point pressure.

The longer the fragment the better the fixation.
The shorter the fragment the poorer the fixation.

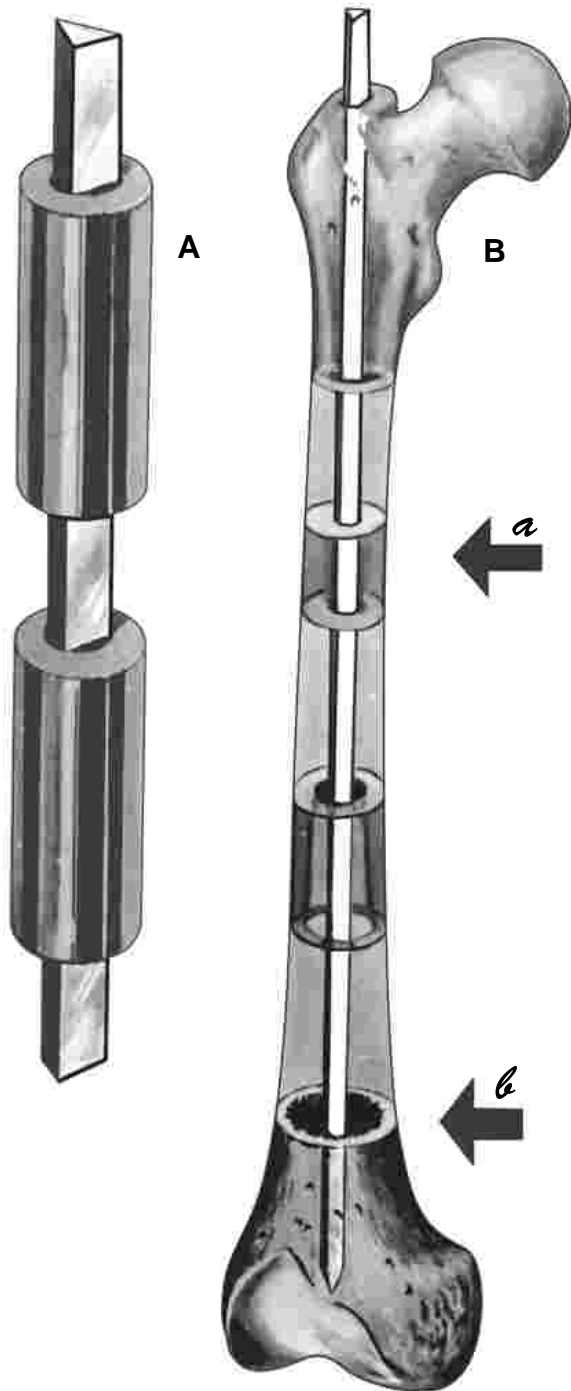


Influence of Other Factors

(A & B) Longitudinal muscle pull compresses fractured bone ends. In smooth transverse fracture (A) rotation might occur. Irregular fracture (B) is securely locked against rotation.
 (C) Pin fitting in natural bone gutters increases stability. Particularly effective in lower radius.

(D) Point set against side of bone or obliquely set in cancellous bone stabilizes distal fragment.
 (E) Transverse muscle pull. Example, three point pressure in neck of humerus fracture increases stability. The various regions of the extremities afford their own peculiar anatomical factors.

Where is the Tight Rod Tight?



(A) A rod can be tightly impacted in a hollow pipe to control rotation because a pipe is of even contour and diameter throughout its entire length.

The medullary cavity of a bone, however, varies both in contour and diameter at various levels. A rod tightly impacted at one level will be loose at another.

(B) **Example femur.** A fracture of the upper half of the femur can be securely transfixed by any type of medullary rod because in this region, the bone is of fairly even diameter.

The medullary cavity is narrowest at the isthmus (a). The lower half of the medullary cavity is large and trumpet-shaped (b).


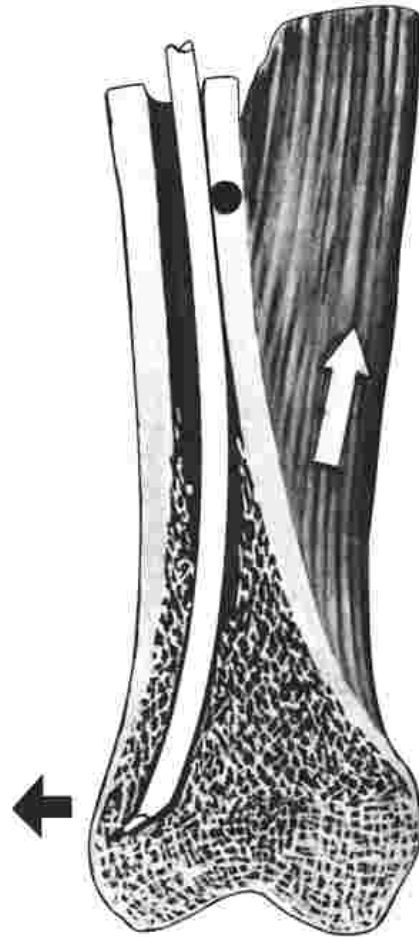
Any rod, which will pass through the isthmus (a), regardless of its shape in cross section, will be loose in the bone at (b).

Such a rod driven straight into the distal fragment must depend solely upon the doubtful firmness of the cancellous bone of the condyles for stability and the prevention of rotation of the lower fragment.

This is reliable only in young, active individuals. Cancellous bone has little substance in debilitated and inactive adults, and is almost absent in the elderly.

It thus becomes apparent that for stability of fixation of the lower fragment, the surgeon must depend not upon the irregularity of cross section of a straight rod, but upon the more dependable dynamic factors which can be utilized.

LOWER FRAGMENT OF FEMUR stabilized by curved pin with point obliquely offset into cancellous bone. The adductor muscles tend to angulate the bone, with pin resisting this force by pressure at two points.



Fixation by straight pin in a curved bone. Proximal fragment of radius (here considered distal fragment) is mildly tortuous in axial contour. A straight pin exerts dynamic pressure at several points.

Distal Fragment

By distal, we here refer to the fragment remote to the point of introduction of the pin. Generally, for maximum stability, the pin is introduced through the shortest fragment. Rare exceptions will be discussed later. Stability of fixation of the distal fragment may be accomplished by:

(1) Driving a straight pin into a curved medullary cavity.

(2) Driving a curved pin into a straight medullary cavity.

(3) Placing the point obliquely into cancellous bone of the extremity of the bone.

NOTE: For good fixation, pin must secure stable purchase on **both** fragments. Otherwise deformity can occur.