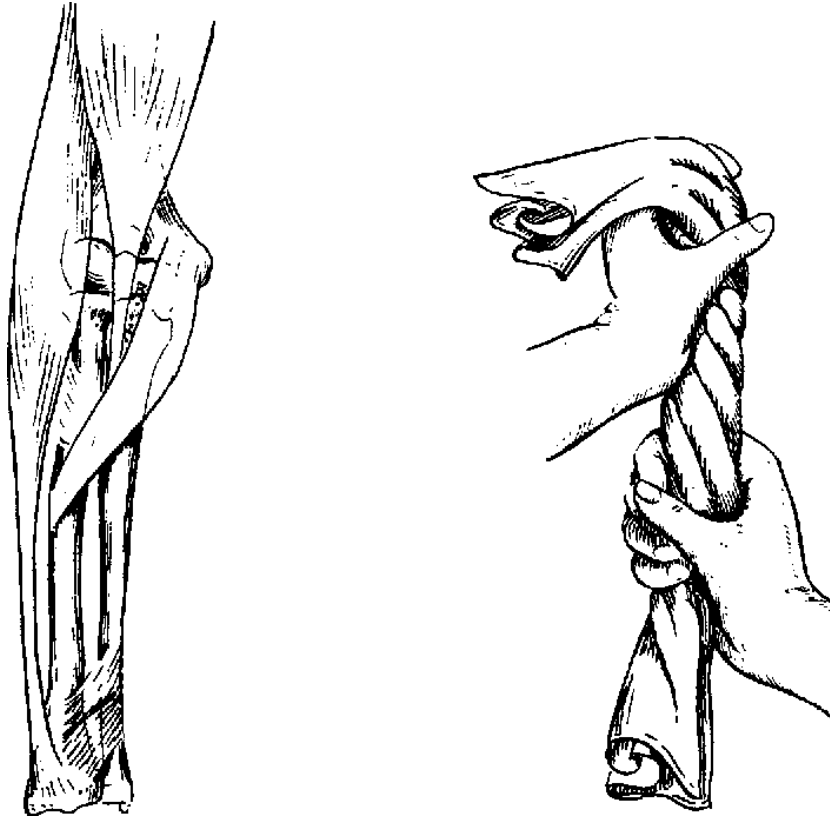


22 THE FOREARM



In the forearm the problem is torque.

Four fragments may have to be dealt with in the forearm. It must be constantly remembered that the forearm controls the hand, providing it with the functions of pronation and supination. The ulna is a fixed bone and plays no part in this function. It is the radius which provides rotation by sliding medially and laterally over the surface of the ulna to rotate the hand.

Non-union occurs rather frequently in fractures of the ulna and can be due to one of many causes. It is usually due to distraction, shear or rotary stress. In the radius non-union has been extremely rare. It is believed that with the proper application of pins non-union will be rare in either bone.

Furthermore, with the proper application of pins in the radius and the ulna, stable fixation can,

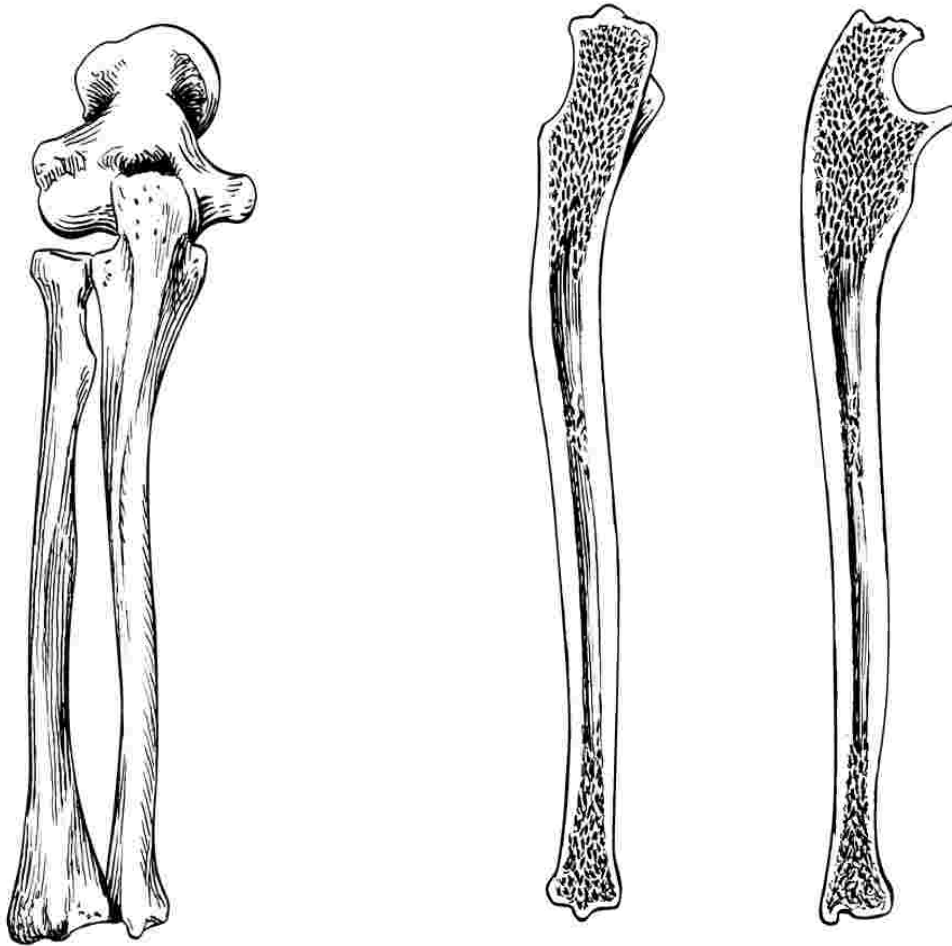
in most instances, be accomplished so that external plaster splints are unnecessary. The exception is the lower extremity of the ulna.

The pins indicated are 1/8 of an inch in diameter and should extend almost the entire length of the respective bones. In a few individuals, the medullary canal is small so that pins 3/32 of an inch in diameter are necessary.

These pins are too small for stable fixation and require, in addition, external plaster splints.

In the event that the fragments of the radius or ulna are held apart by the disparate lengths of the bones, non-union will result, unless the lengths are equalized by step cut operation or a bone graft is done.

If in doubt, SPLINT!



The Ulna

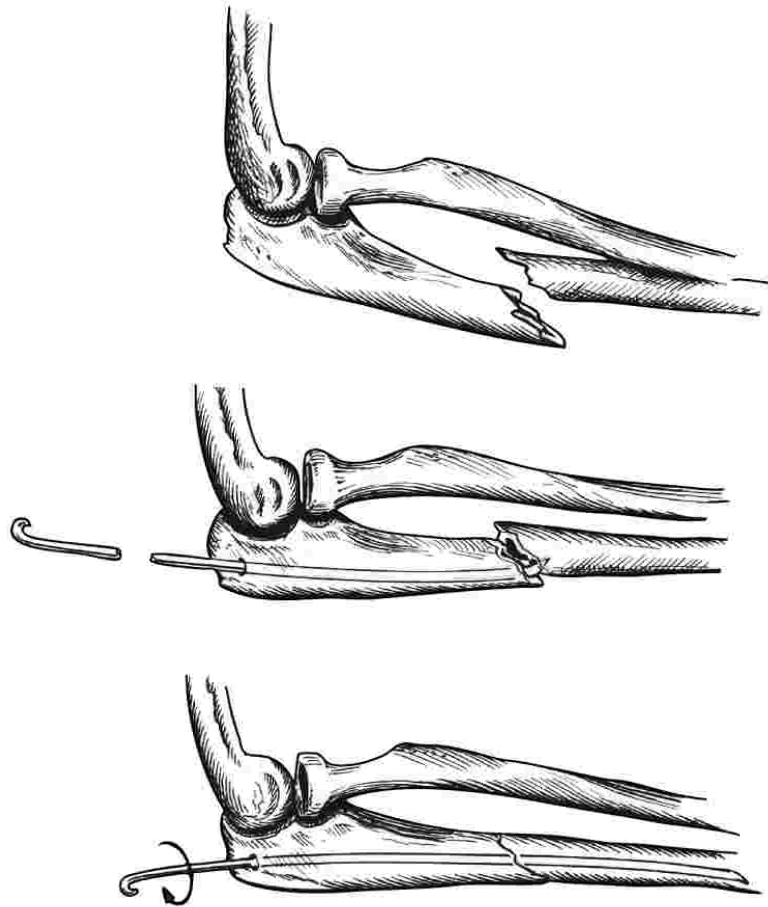
This bone is usually fractured by direct violence. It has few muscle attachments and its displacement is usually a result of the violence and there is some tendency toward displacement of the fragments into the interosseous space. The ulna plays an active role in the mechanism of the elbow and a passive role at the wrist. The fractured ulna does not tend to overlap unless there is an associated fracture of the radius.

The medullary canal of the ulna is somewhat tortuous. A longitudinal section of the bone shows it to be slightly S-shaped in both the antero-posterior and lateral planes. The proximal

half of the bone shows considerable curvature while the lower third of the medullary canal is a relatively straight tube.

If non-union of this bone is to be avoided these contour characteristics must be taken seriously into account in medullary pinning.

If fracture involves the lower third of the ulna, it should be splinted. It is extremely difficult to completely eliminate rotary stress in this area. If fixation is not stable, there is tendency to exuberant callus, delayed union and synostosis, unless splints are applied.



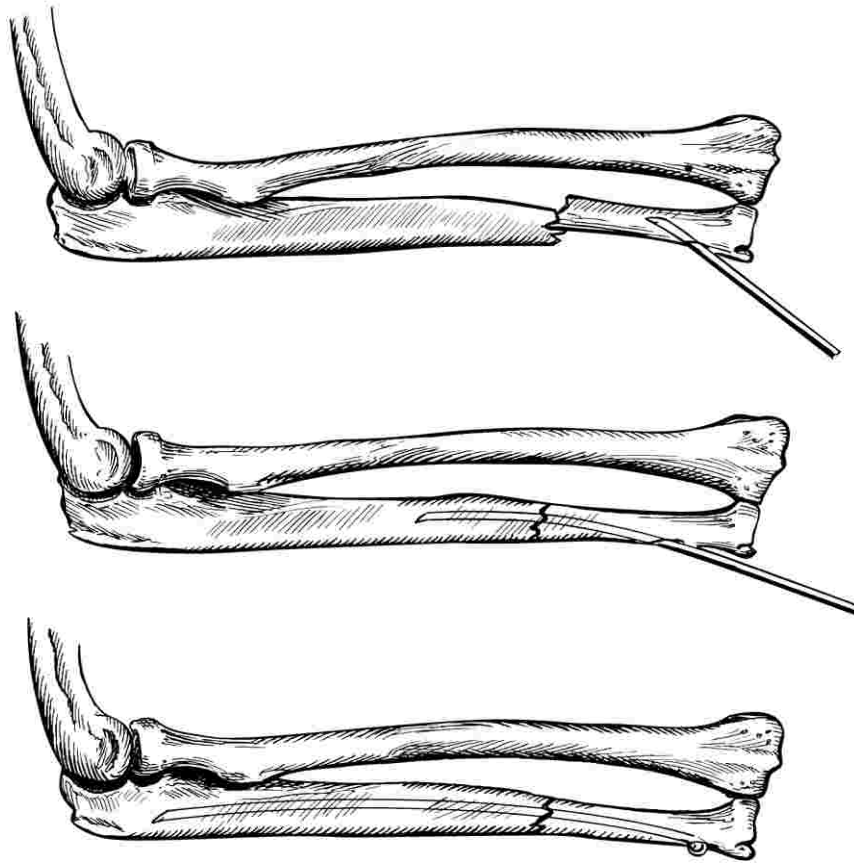
Ulna: Upper Half

In the fracture here depicted non-union could very easily occur. Notice that the shaft fragment is displacing toward the radius. The proximal fragment is tending to angulate dorsally from the pull of the triceps muscle. If reduction and fixation are not excellent, some distraction with lack of compression force will result. Then, upon active motion of the elbow, a shear force is created and rotation of the forearm will produce, in the lower fragment, a tendency to torque.

Technic: It is best to introduce the pin (1/8 inch) through the side of the olecranon. This gives better fixation through three-point pressure and lessens the tendency of the pin to migrate backward. At times it is advantageous to give

the pin a slight curve with the bending iron. When the point of the pin has reached the fracture surface, the pin is rotated so that the point is directed toward the displaced distal fragment. At this stage, the fracture must be reduced and held in perfect position as the pin is driven firmly into the lower end of the distal fragment. The pin is then rotated 180 degrees as it is driven completely home to set the point into the dorsum of the distal fragment. The pin is driven until the hook of the head firmly grasps the cortex of the olecranon. Fixation is usually stable and external splints are rarely needed.

If healing is slow, apply barrel stave iliac grafts without disturbing the fixation.



Ulna: Lower Half

The problem here is a more difficult one. If the technic described on the previous page were utilized in this fracture, the pin would secure excellent fixation of the proximal fragment and relatively no fixation, so far as rotation is concerned, upon the lower fragment. This fragment is a straight tube.

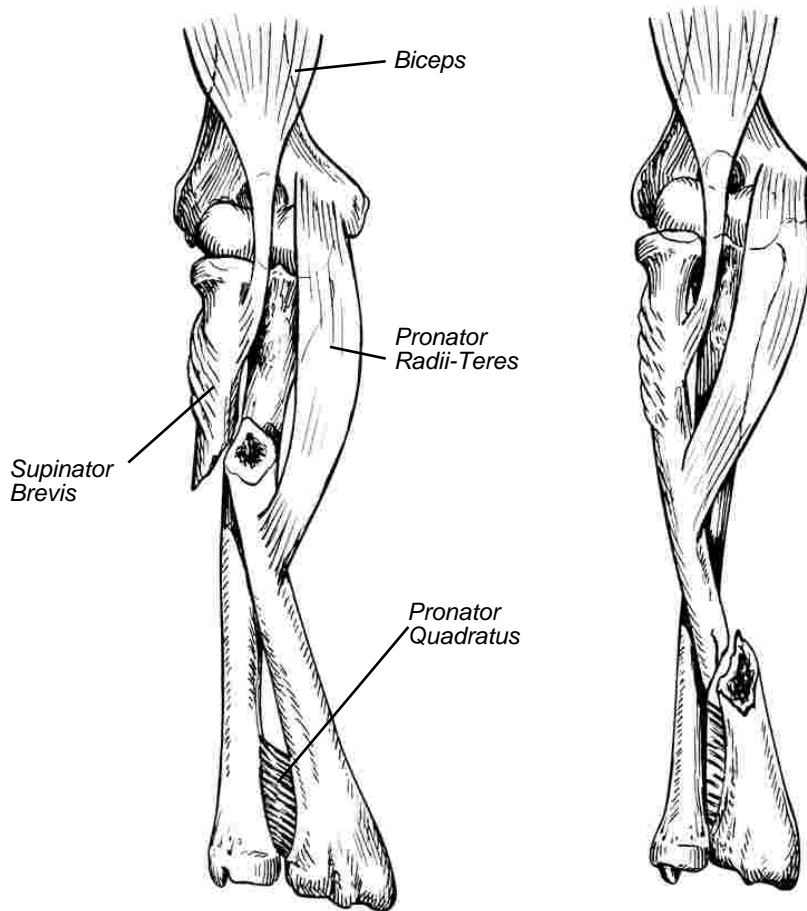
In order to secure stable fixation of the pin upon the lower fragment, it is necessary for the pin to enter this fragment from the side so that it will be forced into a curve within the medullary canal of this fragment. Creating three points of pressure. The proximal fragment is no problem because three points of pressure are created by the passage of the relatively straight pin into the curved bone. Furthermore, the offset point of the pin, which is driven into the cancellous bone of the upper end of the ulna, increases the stability of fixation of this fragment.

In this particular fragment, had the pin been driven downward from the olecranon, three points of pressure would have been wasted upon the upper fragment, while no points of pressure would have been secured in the distal fragment.

In the technic shown, three points of pressure are secured in both the distal and the proximal fragments.

It is much easier to insert the pin through the styloid end of the ulna, but fixation is not as stable. When this point of insertion is used, splinting is often necessary.

Bear in mind that non-union is not infrequent in fractures of the mid-third of the ulna in adults. In such cases, excessive use eventually will cause fracture of the pin. If healing is delayed, consider immobilizing the forearm in plaster or replacement of the pin with application of bone grafts.



Radius: Displacement

The fractured radius is acted upon very violently by muscle pull. Note that the biceps muscle and the supinator are attached to the proximal portion of the shaft and that the pronator quadratus is attached transversely across the lower shaft.

Almost midway between these muscles, at a point slightly above the mid-shaft, is the attachment of the pronator radii teres.

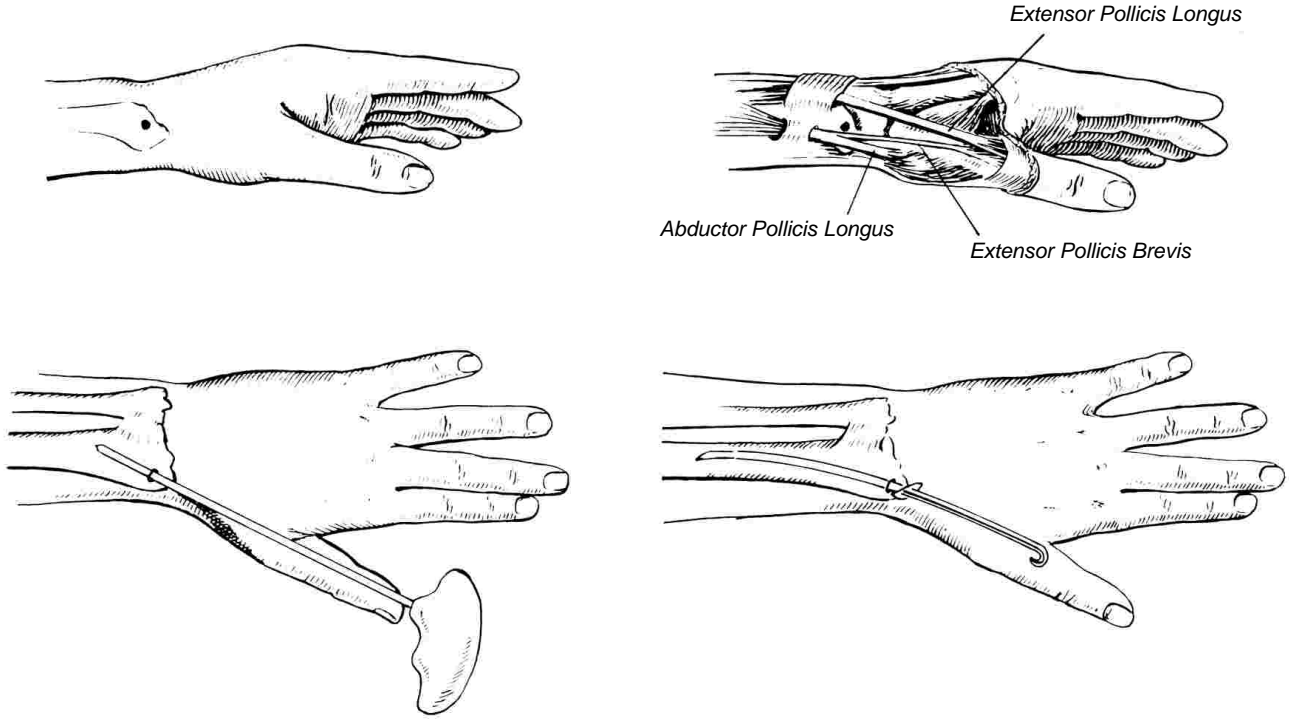
UPPER THIRD

The proximal fragment is acted upon by the supinator and biceps muscles which act unopposed to supinate this fragment. Reduction at this level must be accomplished with the radius held in supination.

THE LOWER TWO-THIRDS

When the fracture is below the insertion of the pronator radii teres, the pronator and supinator muscles very nearly balance each other so that the bone can be treated in the neutral position. There is, however, some tendency toward flexion of the proximal fragment by the pull of the biceps tendon.

Despite the extensive muscle pull upon the radius and its action in rotating the hand, a properly placed pin usually secures very stable fixation because of the tortuosity of the medullary canal in which many points of pressure are established by the pin.



Introduction of Pin into Radius

This is not a difficult procedure. The styloid process of the radius is palpated in the anatomic snuff box at a point mid-way between the abductor and extensor pollicis longus tendons of the thumb.

With a small pointed knife, an incision is made over this area for about 1/4 of an inch, extending through the skin only.

The point of the awl-reamer is pushed through this incision to engage the styloid end of the radius, slightly to the dorsum and at a point near the articular surface of the bone.

When it is felt that the point of the reamer has penetrated the cortex of the bone, the direction of the instrument is changed to closely, but not completely, approximate the long axis of the bone as the instrument is driven to a penetration of 1/2 to 3/4 of an inch.

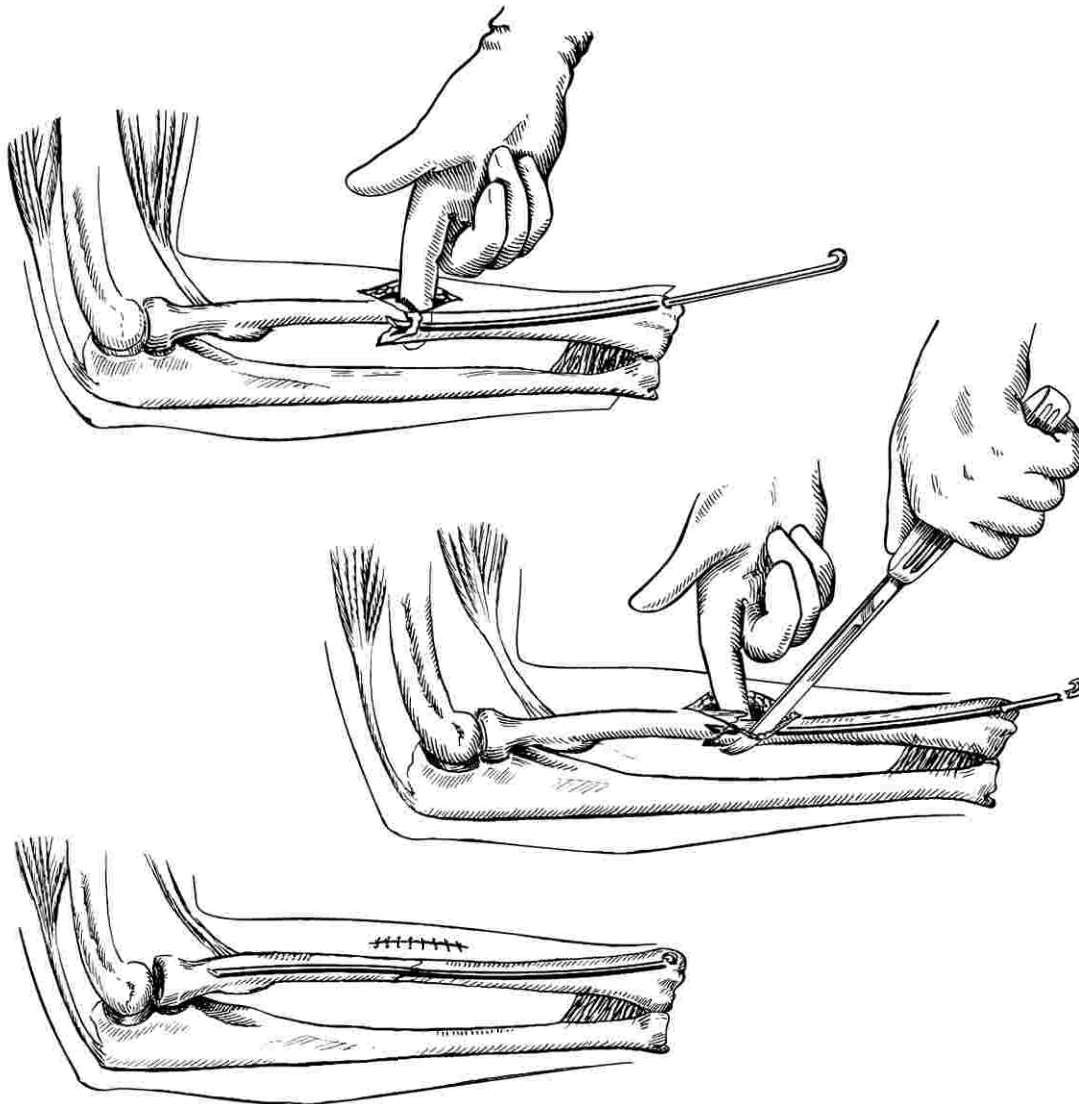
Using the groove in the awl-reamer as a guide,

the point of the pin is pushed into this opening so that the sled runner point will strike the far cortex of the bone and be deflected into the medullary canal as it is driven upward.

In this area, there is some danger of injuring the superficial branches of the radial nerve or of damage to the radial artery or superficial veins, but these structures are usually pushed aside by the careful introduction of the reamer and of the pin.

It is important not to introduce the pin too far to the dorsum or too far proximally, as the head of the pin can become buried beneath the annular ligament or beneath the extensor tendons to make the removal of the pin a frustrating procedure.

When the pin is properly introduced and the head left fairly prominent so that it can be palpated, removal is not at all difficult.



Radius Shaft

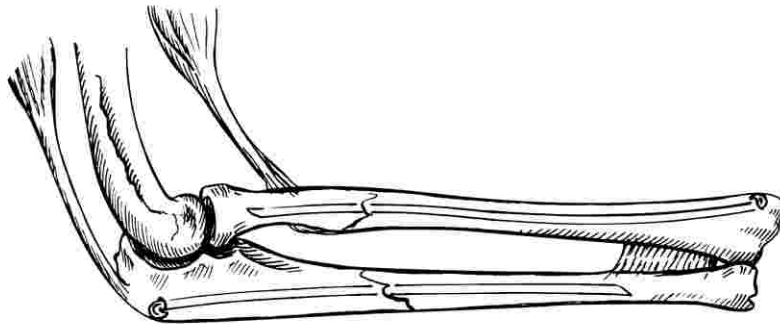
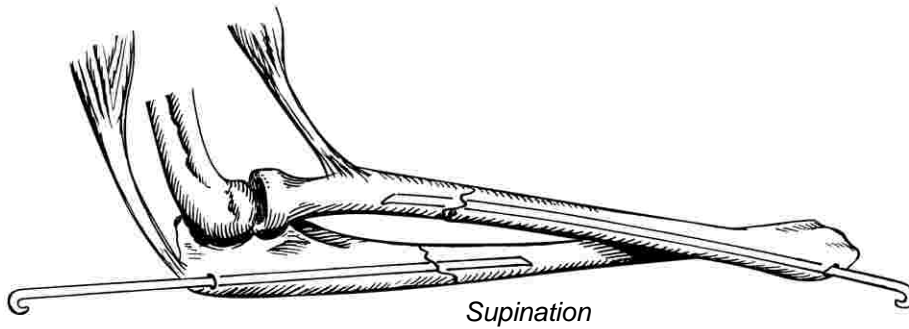
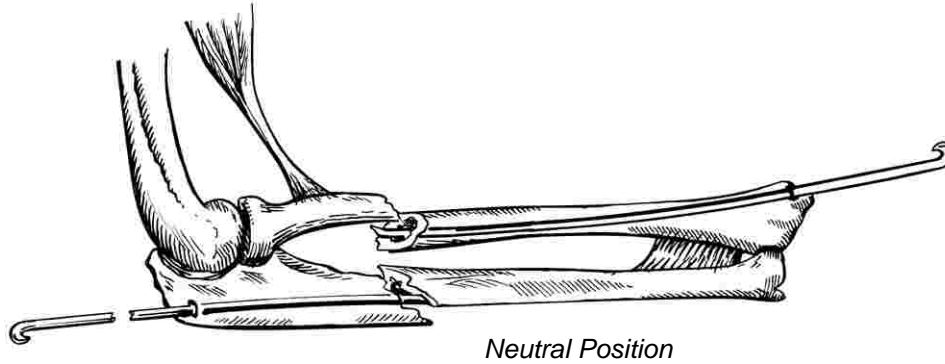
Pinning of the shaft of the radius can often be done by semi-open reduction. The incision is large enough to admit one finger and a periosteal elevator.

The pin is introduced through the styloid end and driven upward to the fracture site before manipulation is done.

The fragments are maneuvered into position and an assistant drives the pin across the fracture to penetrate the proximal fragment about one inch.

When no further adjustments need be made, the pin is driven home. Care should be taken to leave the head slightly prominent so that it can be palpated for later removal. If the head is driven too deeply, the spring pressure will cause it to migrate into the bone. The removal of such a pin can be quite a problem.

Fixation is generally stable so that splints are not needed and full function can be permitted. Good healing can usually be expected.



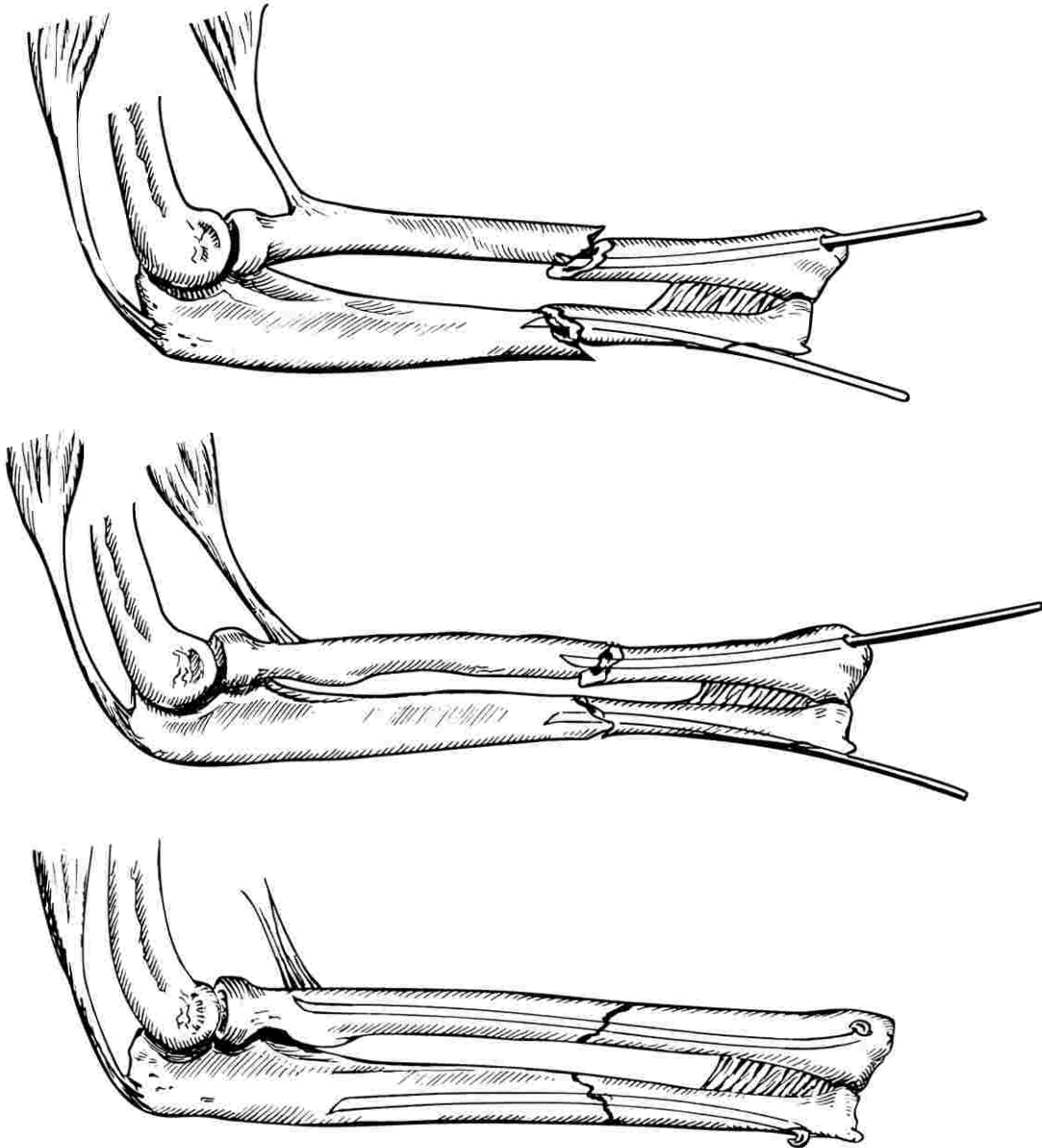
Technic: Both Bones - Upper Third

Through suitable incisions, both fractures are exposed for orientation. The ulna pin is introduced through the side of the olecranon and driven down to the fracture surface. The fracture is reduced and the ulna pin is driven downward for one or two inches beyond the fracture line.

The radius pin is introduced through the styloid end and driven upward to the fracture line. The radius is reduced and the pin driven for about

one inch into the proximal fragment. It is often necessary to bring the forearm into supination to accomplish reduction. Any necessary adjustments of the respective fractures are then made and the pins are driven home.

In all forearm fractures, one must be careful that a distal fragment is not rotated upon the proximal one when it is pinned. This can cause permanent loss of rotary function in the forearm.



Technic: Both Bones - Lower Third

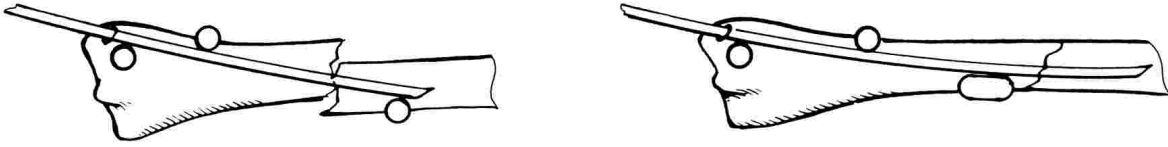Suitable incisions are made over the fractures of the radius and ulna, respectively. The pin is introduced through the styloid end of the radius and driven upward to the fracture surface. The ulna pin is introduced through the lateral surface of the distal end of the ulna and driven upward to the fracture surface. The fracture of the radius is then reduced and the radius pin driven upward into the proximal fragment for about one inch.

The ulna fracture is next reduced and the ulna

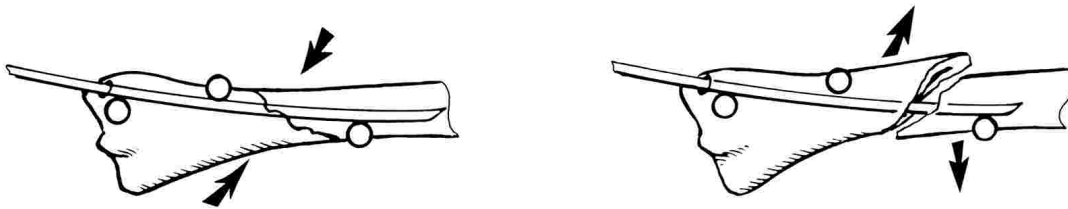
pin driven upward into the proximal fragment for about one inch.

Then, adjustments are made on the respective fractures and the pins are driven home leaving the heads of both pins slightly prominent to facilitate later removal. Plaster splints are not always necessary but might be used advantageously until the soft tissues are healed and should be applied if there is doubt as to the stability of fixation.

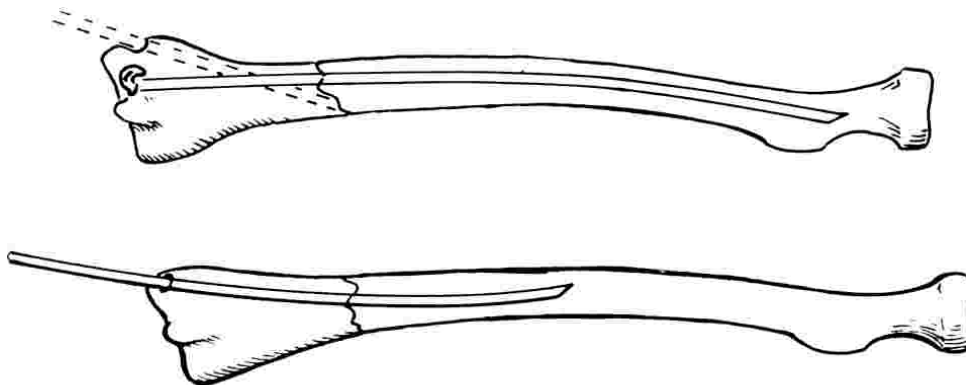
Technical Considerations



Influence of length of fragment radius. Note pressure points. At left pin does not parallel cortex closely enough.



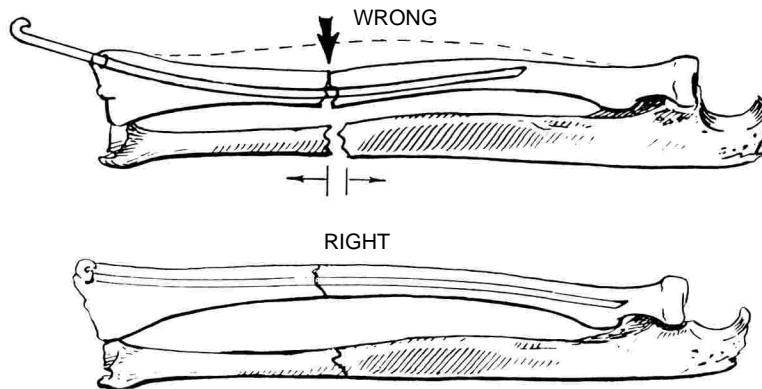
RADIUS: Oblique fractures short fragment. On left good fixation. On right pin introduced at wrong angle, should more closely parallel cortex and proximal end of pin must be sharply stress relieved.



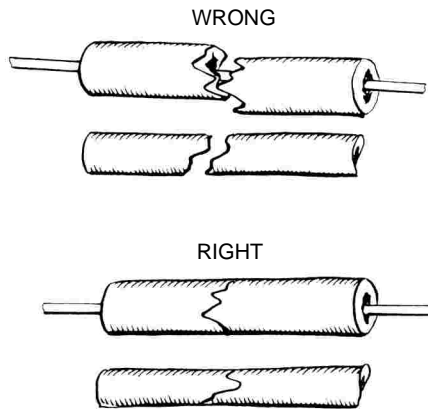
TOP: Bulbous radial styloid makes insertion of pin difficult. Choose point of entrance nearer Lister's tubercle.

BOTTOM: Average radius with routine insertion of pin.

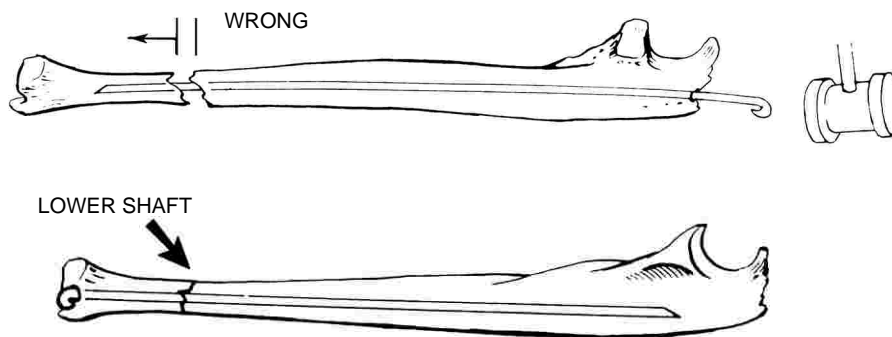
The Forearm



Pin inserted in radius at too much angle becomes curved within the bone and can distract ulna by increasing length of radius.



Incomplete reduction of one bone of the forearm can produce distraction of its fellows.



In lower ulna shaft fractures, it is best to insert pin through the styloid end to prevent distraction.